

Imaging Case of the Month

Solitary Plasmacytoma in the Internal Auditory Canal and Cerebellopontine Angle Mimicking Meningioma

*Joel Lavinsky, †Ksenia A. Aaron, ‡Eisha Christian, §John L. Go, ¶Kyle Hurth,
‡Steven L. Giannotta, and †Rick A. Friedman

**Federal University of Rio Grande do Sul, Porto Alegre, Rio Grande do Sul, Brazil; Department of Otolaryngology, Zilkha Neurogenetic Institute, Keck School of Medicine of the University of Southern California, Los Angeles, California; †Department of Otolaryngology–Head and Neck Surgery; ‡Department of Neurosurgery; §Department of Radiology; and ¶Department of Pathology, Keck School of Medicine of the University of Southern California, Los Angeles, California, U.S.A.*

Plasmacytoma, a non-Hodgkin's lymphoma, arises from a monoclonal proliferation of plasma cells. Solitary extraosseous (extramedullary) plasmacytomas (SEPs) represent 4% of plasma cell neoplasms (1). Between 80% and 90% of SEPs localize to the upper respiratory tract and may involve cervical lymph nodes in ~15% of cases (2). Isolated SEPs showing dural infiltration may mimic meningioma because of their similar appearance on magnetic resonance imaging (MRI) (3). Given that the MRI findings of intracranial plasmacytoma are not specific, final diagnosis is confirmed by histopathologic examination. We report a case of SEP in a patient with a cerebellopontine angle (CPA) mass originally thought to be a meningioma.

CASE REPORT

A 65-year-old Caucasian female presented with progressive left-sided hearing loss and vertigo for 6 months. Her history included hypertension and breast cancer diagnosed 10 years ago (treated with mastectomy and chemotherapy). Physical examination was within normal limits except for Weber test lateralizing to the right and a positive Rinne test bilaterally. Audiologic analysis revealed profound sensorineural hearing loss on the left with a pure tone average of 80 dB. Given the unilateral hearing loss, MRI was done showing a $4.7 \times 5.1 \times 1.7$ cm of extra axial mass in the left CPA (Fig. 1). T1- and T2-weighted images revealed an isointense mass (Fig. 1, A and B). Postcontrast T1-weighted images showed a homogeneous avidly enhancing mass arising from the dura with extension into the CPA and the internal auditory canal (Fig. 1C). Given severe sensorineural hearing

loss, and tumor site, a translabyrinthine craniotomy was performed. The dura was extensively invaded by the tumor. Frozen sections showed a malignant neoplasm not diagnostic of a meningioma. Radical CPA tumor decompression was completed, and the incision was closed.

Microscopic examination (Fig. 2A) revealed a sheet-like growth pattern of plasmacytoid-shaped cells with amphophilic cytoplasm, perinuclear clearing (hofs), and stippled chromatin. The cells were positive for CD138 (Fig. 2B) and kappa (κ) light chain (Fig. 2C), and were negative for λ light-chain. Final diagnosis was plasma cell neoplasm. Postoperatively, patient's facial nerve function was preserved and vertigo resolved. Three-month postoperative MRI showed evidence of residual disease. The patient was prescribed postoperative 5000-cGy radiotherapy. Evaluation for plasma cell myeloma (PCM) by lumbar puncture, skeletal survey, and urine protein electrophoresis for Bence–Jones proteins, was negative.

DISCUSSION

Dural plasmacytoma is a rare form of SEP. Isolated dural posterior fossa SEP, without bony involvement or concurrent diagnosis of PCM, is very rare and (to the best of our knowledge) has not been reported in the literature. Although two thirds of patients with SEPs are men, dural SEPs have a reported female predominance of 84% and mean age at diagnosis is 50.2 years (4). Around 20% of patients with an SEP have a small M-protein by electrophoresis of urine or serum with no clinical features of PCM (1).

The neuroradiological findings of SEP lack specificity and may mimic lymphoma, metastasis, sarcoma, or meningioma (3,5). Final diagnosis is based on the demonstration of a clonal proliferation of plasma cells usually with immunohistochemical staining (1,2). Plasma cells express CD138, and clonality can be

Address correspondence and reprint requests to Ksenia Aaron, M.D., USC Tina and Rick Caruso Department of Otolaryngology–Head and Neck Surgery, 1540 Alcazar Street, Room 204S, Los Angeles, CA 90033, U.S.A. E-mail: ksenia.aaron@med.usca.edu

The authors disclose no conflicts of interest.

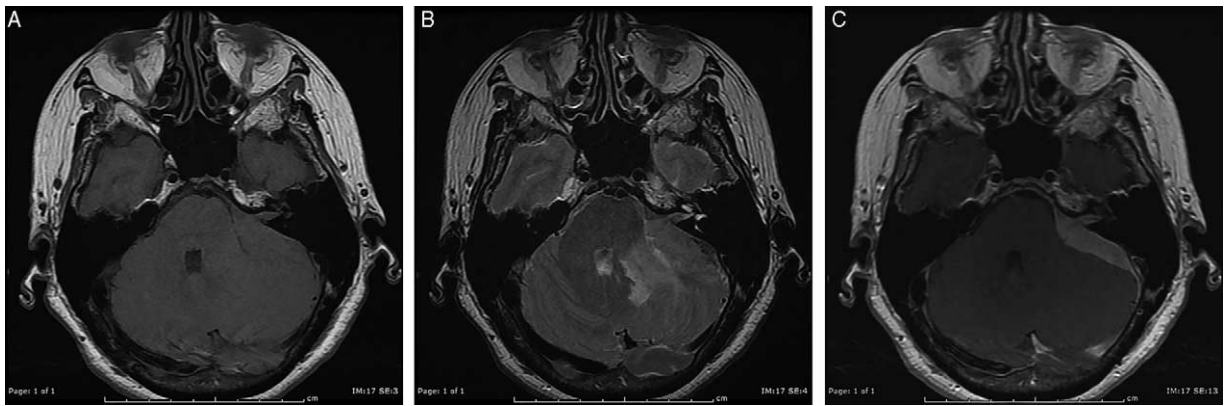

FIG. 1. Preoperative brain MRI axial images. *A*, T1-WI demonstrates an isointense to gray matter signal—intense dural-based mass at the left CPA extending into and filling the internal auditory canal. The mass exerts a mild degree of mass effect on the brachium pontis. *B*, Fast spin echo T2-WI demonstrates the mass to be isointense (note the hyperintense signal within the brachium pontis and the deep white matter of the cerebellum, which may represent edema). *C*, Postcontrast T1-WI shows homogeneous avid enhancement mass that appears to rise from and follow the dura along the CPA extending into the IAC. CPA indicates cerebellopontine angle; IAC, internal auditory canal; MRI, magnetic resonance imaging; WI, weighted image.




FIG. 2. Immunohistochemical characteristics of plasmacytoma. *A*, A hematoxylin and eosin—stained section ($\times 100$ objective) shows densely packed plasmacytoid-shaped cells with a sheet-like growth pattern that are (*B*) positive by CD138 immunostaining ($\times 100$ objective) and (*C*) positive for κ light-chain by in situ hybridization ($\times 100$ objective).

demonstrated by light-chain restriction. SEP involving the head and neck has an excellent prognosis, with more than 70% of patients surviving greater than 10 years. Literature review and the present study support the use of postoperative radiotherapy because SEPs are highly radiosensitive (1–4). Progression of SEP to PCM is reported to occur in $\sim 15\%$ of cases (1). The patient in our case is currently being followed.

Although meningioma commonly enters the differential of a dural based mass in the CPA, one may also entertain the possibility of unexpected entities, including SEP, as this case demonstrates. Management of SEP should include resection followed by radiotherapy.

REFERENCES

1. Swerdlow SH, Campo E, Harris NL, et al. *WHO Classification of Tumours of Haematopoietic and Lymphoid Tissue*, IARC Press, 2008; 200–13.
2. Chiang SK, Canalis RF, Ishiyama A, et al. Plasmacytoma of the temporal bone. *Am J Otolaryngol* 1998;19:267–73.
3. Sahin F, Saydam G, Ertan Y, et al. Dural plasmacytoma mimicking meningioma in a patient with multiple myeloma. *J Clin Neurosci* 2006;13:259–61.
4. Kremer S, Grand S, Remy C, et al. Contribution of dynamic contrast MR imaging to the differentiation between dural metastasis and meningioma. *Neuroradiology* 2004;46:Error: FPage (642) is higher than LPage (8)!
5. Manabe M, Kanashima H, Yoshii Y, et al. Extramedullary plasmacytoma of the dura mimicking meningioma. *Int J Hematol* 2010;91:Error: FPage (731) is higher than LPage (2)!